

DIAGNOSTIC CHALLENGE

A swimmer's wheeze

Brian Deady, MD;* James Glezos, MD;† Stephen Blackie, MD†

Case history

A previously healthy 38-year-old triathlete prepared for a swim in a cold (15°C) lake by drinking 1/2 L of a protein supplement and putting on a wetsuit. After swimming approximately 500 m, she developed dyspnea. She stopped momentarily and then continued on, but developed further dyspnea associated with chest constriction and wheezing. Her exercise tolerance deteriorated dramatically, such that she had to be towed to shore by another swimmer. Throughout the swim and rescue procedure her head was not submerged and she did not aspirate lake water.

Upon reaching the shore, the patient's symptoms continued, and she also developed hemoptysis. Nevertheless, she was able to drive herself to the the emergency department at the nearest hospital, 15 minutes away.

In the emergency department, the patient was found to be in moderate respiratory distress, tachypneic, able to speak only in brief phrases, and profoundly hypoxemic (blood pressure = 119/72 mm Hg; heart rate = 72 beats/min; respiratory rate = 32 breaths/min; SaO₂ = 72% on room air). There was no jugular venous distension, no cardiac murmurs or gallops, and no dependent edema, but there was diffuse wheezing on auscultation of the chest.

Laboratory investigations showed borderline elevation of the D-dimer, but results of troponin I tests and the ECG were normal. The initial sitting anterior-posterior chest x-ray is shown in Figure 1.

This patient's most likely diagnosis is:

- a) food-associated exercise-induced anaphylaxis;
- b) cold urticaria;
- c) swimming-induced pulmonary edema; or
- d) cardiogenic pulmonary edema.

For the Answer to this Challenge, see page 297.

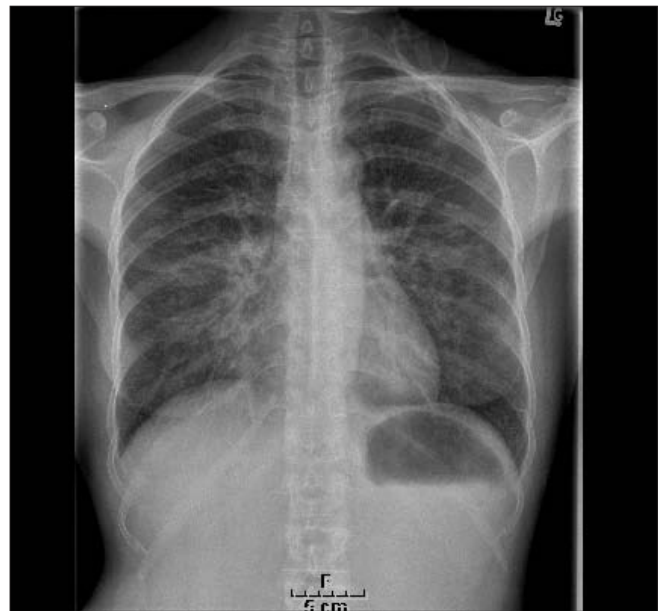


Fig. 1. Results of the initial sitting anterior-posterior chest x-ray

From the *Emergency Department, and the †Division of Respiratory and Critical Care Medicine, Royal Columbian Hospital, New Westminster, BC

Received: Jan. 4, 2006; accepted: Jan. 30, 2006

This article has been peer reviewed.

Can J Emerg Med 2006;8(4):281

DIAGNOSTIC CHALLENGE

Answer

Brian Deady, MD;* James Glezos, MD;† Stephen Blackie, MD†

The correct answer to this Diagnostic Challenge is swimming-induced pulmonary edema (SIPE).

Cardiogenic pulmonary edema is an unlikely diagnosis in this case. Even without knowing the results of serial troponin determinations, the diagnosis of acute myocardial infarction leading to severe congestive heart failure would be almost impossible with a normal ECG; and as indicated below. Of note, a delayed echocardiogram revealed a normal ejection fraction, suggesting a non-cardiogenic etiology.

Food-associated, exercise-induced anaphylaxis has been described,¹ especially in teenaged women, and it can produce pulmonary edema;² however, this patient lacked wheals and gastrointestinal symptoms, as well as vascular collapse, which are key features of the syndrome.

Cold urticaria may often involve the respiratory tract (hoarseness, dyspnea and wheezing), gastrointestinal and the cardiovascular systems (hypotension, tachycardia and arrhythmia),³ and shock-like symptoms have been reported after aquatic exposures.^{4,5} However, most typically patients with this condition develop diffuse pruritus and wheals with angioedema,³ and our patient had none of these manifestations.

Commentary

In racing thoroughbreds, marked increases in pulmonary vascular pressures contribute to stress failure of pulmonary capillaries^{6,7} causing lung bleeding. After brief, vigorous exercise in elite human athletes with a previous history suggestive of lung bleeding, increased concentrations of red blood cells and protein have been demonstrated in broncho-alveolar lavage fluid. These findings imply that

intense exercise can impair the integrity of the pulmonary capillaries of the blood–gas barrier (BGB).⁸ Chest CT scans of highly trained athletes after a triathlon competition demonstrated enhanced lung density and greater numbers of opacities suggesting an increase in pulmonary extravascular fluid.⁹

Although rare in people exercising on land, pulmonary edema is more routinely reported in individuals participating in swimming or other immersion-related sports.¹⁰ Adir and coworkers describe a series of 70 teen athletes who, over a 3-year period, developed SIPE.¹⁰ All cases occurred in trainees who were swimming semi-reclined in warm

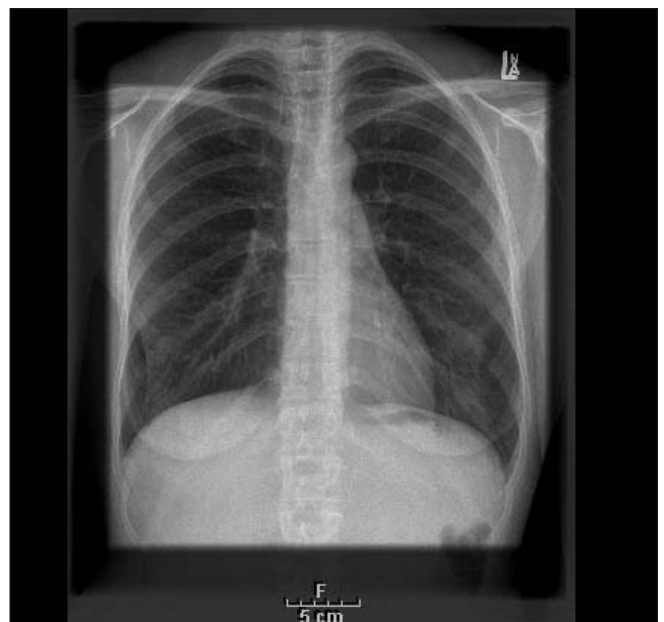

Fig. 1. Results of chest x-ray taken 5 days after the incident.

From the *Emergency Department, and the †Division of Respiratory and Critical Care Medicine, Royal Columbian Hospital, New Westminster, BC

Can J Emerg Med 2006;8(4):297-8

seawater and wearing fins. Similarly, Koehle and associates reviewed 60 published cases of immersion-induced pulmonary edema in 56 individuals. Only 9 cases were associated with endurance swimming. The rest were associated with scuba diving and breath-hold diving.¹¹ Three cases of right-sided pulmonary edema were described in men who swam right side down during US Navy SEAL training manoeuvres.¹²

The mechanism by which cold-water immersion and exercise lead to a pulmonary capillary leak is probably related to a sudden increase in right ventricular preload and increased pulmonary artery pressures.¹⁰⁻¹³ Increased preload is due to cold-induced vasoconstriction, which can lead to an increase in the left ventricular afterload; and this, in turn, can contribute to pulmonary edema. Even if a swimmer is wearing a wetsuit, vasoconstriction can occur.¹⁰⁻¹³ Excessive volume loading before exercising may also play a role as 8 cases of SIPE were identified in military recruits who drank 5 L of water before exercise.¹⁴

Interestingly, there have been no reports of SIPE in Olympic swimmers, but there is one case published of a triathlete who developed dyspnea with slight hypoxia and right-sided pulmonary crackles some 8–9 hours after the swim. Results of the chest x-ray in this case were normal.¹⁵

Epilogue

The patient was warmed and dried, given supplemental oxygen via face mask, and 20 mg of furosemide was administered intravenously. Her respiratory distress and hemoptysis rapidly resolved. A second troponin measured 24 hours later was normal, as was a transthoracic echocardiogram. Five days later, results of a second chest x-ray were completely normal (Fig. 1, previous page).

Competing interests: None declared.

Key words: dyspnea; wheeze; hemoptysis; swimming

References

1. Woo MY, Cwinn AA, Dickinson G, et al. Food-dependent exercise-induced anaphylaxis. *Can J Emerg Med* 2001;3(4):315-7.
2. Sampson HA, Leung DYM. Adverse reactions to foods. In: Behrman RE, Kliegman RM, Jenson HB, editors. *Nelson textbook of pediatrics*, 17th ed. Saunders, Elsevier Science; 2004. p. 789-92.
3. Kim G. Primary (idiopathic) cold urticaria and cholinergic urticaria. *DOJ* 2004;10(3):13 http://dermatology.cdlib.org/103/NYU/case_presentations/031604n5.html#4
4. Wanderer AA. Cold urticaria syndromes: historical background, diagnostic classification, clinical and laboratory characteristics, pathogenesis and management. *J Allergy Clin Immunol* 1990; 85:965.
5. Mathelier-Fusade P, Assaoui M, Bakhos D, et al. Clinical predictive factors of severity in cold urticaria. *Arch Dermatol* 1998;134:106-7.
6. Erickson BK, Erickson HH, Coffman JR. Pulmonary artery, aortic and oesophageal pressures g during high intensity exercise treadmill exercise in the horse: a possible relation to exercise-induced pulmonary haemorrhage. *Equine Vet J* 1990;9(suppl):47-52.
7. Manohar M. Pulmonary wedge pressure increases with high-intensity exercise in horses. *Am J Vet Res* 1993;54:142-6.
8. Hopkins SR, Schoene RB, Henderson WR, et al. Intense exercise impairs the integrity of the pulmonary capillaries of the pulmonary blood-gas barrier in elite athletes. *Am J Respir Crit Care Med* 1997;155:1090-4.
9. Caillaud C, Serre-Cousine O, Anselme F, et al. Computerized tomography and pulmonary diffusing capacity in highly trained athletes after performing a triathlon. *J Appl Physiol* 1995;79:1226-32.
10. Adir Y, Shupak A, Gil A, et al. Swimming-induced pulmonary edema: clinical presentation and serial lung function. *Chest* 2004;126:394-9.
11. Koehle MS, Lepawsky M, McKenzie DC. Pulmonary oedema of immersion. *Sports Med* 2005;35:183-90.
12. Lund KL, Mahon RT, Tanen DA, et al. Swimming-induced pulmonary edema. *Ann Emerg Med* 2003;41:251-6.
13. Shupak A, Weiler-Ravel D, Adir Y, et al. Pulmonary oedema induced by strenuous swimming: a field study. *Respir Physiol* 2000;121:125-31.
14. Weiler-Ravell D, Shupak A, Goldenberg I, et al. Pulmonary oedema and haemoptysis induced by strenuous swimming. *BMJ* 1995;311:361-2.
15. Biswas R, Shibu PK, James CM. Pulmonary oedema precipitated by cold water swimming. *Br J Sports Med* 2004;38:36.

For the Challenge, see page 281.

Correspondence to: Dr. Brian Deady, Emergency Department, Royal Columbian Hospital, 330 East Columbia St., New Westminster BC V3L 3W7